

Fwd: Dani Araya carta de reporte

Carl Hewlett

Mon, Jun 29, 12:18 PM
(4 days ago)

Dear Brethren,

Here is a most recent report from Missionary Danny Araya in Costa Rica.

Bro. Carl, GPA
Luke 19:10

Pastor Daniel Araya Vindas

Cel. (506) 8706-8345



Libre de virus. www.avast.com

One attachment • Scanned by Gmail
Missionary Araya, Costa Rica Report

Prayer Request Letter

Dear Pastor and Beloved Church Family,

With a humble and burdened heart, we are writing to ask your prayers for Zilenia Corrales, the wife of Missionary Luis Corrales in Venezuela.

Zilenia has already walked through a very difficult season. For three years she battled breast cancer, and by the grace of God she was able to overcome that trial. Recently, however, her doctors identified a pulmonary nodule described in her chest CT report as suggestive of metastasis.

The medical team has recommended a procedure to remove the pulmonary nodule. The estimated cost of this procedure is \$7,274.44. A copy of the CT Scan report and a form listing the medical costs involved have been attached.

At this time, we are asking the Lord's people for two things. First, please pray that God would strengthen Zilenia, give her peace, guide the doctors, provide wisdom for every decision, and grant her the healing she needs according to His perfect will.

Second, if the Lord places it on your heart, and if any brother, family, or church would like to help with this medical need, any contribution would be received with deep gratitude. This request is made with the highest respect, without pressure, and with full consideration for each church's own responsibilities and burdens.

Brother Luis and his wife have served the Lord faithfully in Venezuela, and during this painful time they need the prayers, love, and encouragement of God's people. Your compassion would be a blessing not only to Zilenia, but also to her husband and their children as they face this new trial together.

Thank you for taking the time to read this request, for praying, and for considering whether the Lord would have you participate in this need. May God bless you and your church for your love toward His servants.

If you would like to help the Corrales family, you may do so in one of two ways. You may mail a check to [GPA Missions, P.O. Box 520, Oxford, PA 19363](mailto:GPA_Missions@GPA_Missions.org). Please write CORRALES SURGERY on the memo line.

You may also give online at: https://www.paypal.com/donate/?hosted_button_id=YBX326XFP2XRG
An online offering will be received immediately. It is the same as sending it by regular mail, only faster and more secure.

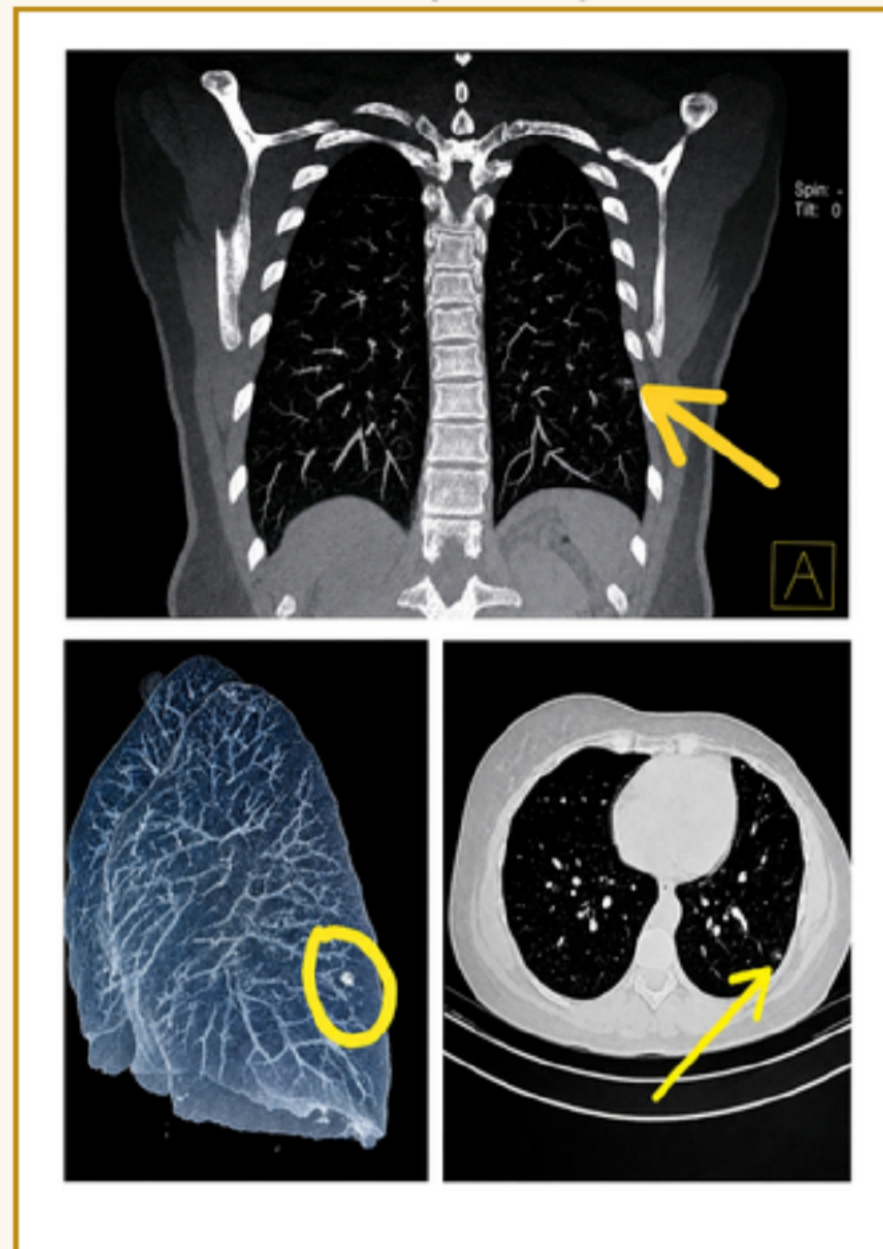
If you decide to send an offering for the Corrales family, please let me know so I can promptly inform Brother Corrales.

With Christian love and gratitude,
Carl Hewlett
Luke 19:10



Medical Diagnostic Impression

Chest CT report reference



IDB
INSTITUTO DIAGNOSTICO
BARQUISIMETO

INSTITUTO DIAGNOSTICO BARQUISIMETO, C.A.
RIF: J-30355646-9

REPORT

Gallbladder and bile ducts appear normal.

Pancreas, spleen, and adrenal glands without evidence of abnormalities.

Regional skeleton without evidence of lytic or blastic lesions or fractures.

DIAGNOSTIC IMPRESSION OF CHEST CT SCAN (CT-0626-167), PATIENT CASTILLO DE CORRALES TAIMAR,
DATE: JUNE 16, 2026:

NODULAR LESION WITH A "GROUND-GLASS" HALO IN THE LATERAL SEGMENT OF THE LEFT LOWER LOBE, NOT SEEN IN THE PREVIOUS STUDY, SUGGESTIVE OF METASTASIS (MT).


POST-RADIATION CHANGES IN THE LEFT LUNG, SIMILAR TO THOSE OBSERVED IN THE PREVIOUS STUDY.

CALCIFICATION IN THE PREVASCULAR SPACE, SIMILAR TO WHAT WAS OBSERVED IN THE PREVIOUS STUDY.


CALCIFIED ATHEROMATOUS PLAQUES IN THE AORTIC ARCH, SIMILAR TO WHAT WAS OBSERVED IN THE PREVIOUS STUDY.

LEFT RADICAL MASTECTOMY.

RESPECTFULLY,


Dr. Maria E. Velasco
C. 4.394.253

DR. MARIA E. VELASCO
RADIOLOGIST


Dr. Giovanni Adami
MEDICO RADIOLÓGICO
C. 1.648.815
MÉDICO JEFE C.M.I. AMB

DR. ADAMI R. GIOVANNY P.
RADIOLOGIST


KS

The medical images are shown above the diagnostic report for reference and prayer support.

Medical Estimate

Pulmonary nodule resection - total estimate shown below

Total Estimate: \$7,274.44



CENTRO MÉDICO DE ONCOLOGÍA, C.A
 J-08518644-1
 CALLE 41 ENTRE AV 20 Y CARRERA 21 EDIF CENTRO MEDICO DE ONCOLOGIA BARQUISIMETO -
 Telf: (0251) 2407525 / 2407526 / 4466855 / 2407500

ESTIMATE
00012746

ISSUED: 29/06/2026 **VALID UNTIL:** 02/07/2026

PATIENT: TAIMAR ZILENIA CASTILLO **ID:** _____
ADDRESS: _____
PHONE: _____

ACCOUNT HOLDER: TAIMAR ZILENIA CASTILLO **ID:** _____

PROCEDURE: PULMONARY NODULE RESECTION
DIAGNOSIS: PULMONARY NODULE RESECTION
PAYMENT METHOD: CASH
ATTENDING PHYSICIAN: ANDREINA BERRIOS BRICEÑO

DESCRIPTION	ALIC	QTY	TOTAL US\$	TOTAL Bs
HOSPITALIZATION SERVICES			632.03	393,767.33
PRIVATE HOSPITAL ROOM S/PRV 294	(E)	3.00	0.03	18.69
ADMISSION AND INTAKE (ONE-TIME FEE)	(E)	1.00	47.00	29,281.94
FOOD AND NUTRITION SERVICES (PER DAY)	(E)	3.00	165.00	102,798.30
RESIDENT PHYSICIAN AVAILABILITY DURING HOSPITALIZATION (PER DAY)	(E)	3.00	300.00	186,906.00
NURSING SERVICE (INPATIENT)	(E)	3.00	120.00	74,762.40
OPERATING ROOM SERVICES			456.01	284,103.35
STANDARD OPERATING ROOM S/PRV 294	(E)	1.00	0.01	6.23
MEDICAL EQUIPMENT REPLACEMENT COSTS IN THE OPERATING ROOM (UP TO 2 HOURS)	(E)	1.00	160.00	99,683.20
OPERATING ROOM SCRUB NURSE (UP TO 2 HOURS)	(E)	1.00	60.00	37,381.20
MEDICAL OXYGEN GASES (PER HOUR)	(E)	2.00	180.00	112,143.60
OXYGEN RECOVERY ROOM	(E)	1.00	56.00	34,889.12
ANATOMICAL PATHOLOGY SERVICES			216.00	134,572.32
PATHOLOGIST FEES - LARGE BIOPSY	(E)	2.00	216.00	134,572.32
BLOOD BANK SERVICES			20.40	12,709.61
BLOOD TYPE, RH FACTOR, AND INDIRECT COOMBS	(E)	1.00	20.40	12,709.61
MEDICATIONS			850.00	529,567.00
MEDICATIONS	(E)	1.00	850.00	529,567.00
SURGICAL MEDICAL SUPPLIES			1,120.00	697,782.40
MATERIALS	(E)	1.00	1,120.00	697,782.40
THIRD-PARTY CHARGES UNDER ARTICLE 10 OF THE VAT LAW			3,980.00	2,479,619.60
PRIMARY SURGEON	(E)	1.00	1,800.00	1,121,436.00
FIRST ASSISTANT	(E)	1.00	720.00	448,574.40
SECOND ASSISTANT	(E)	1.00	540.00	336,430.80
ANESTHESIOLOGIST	(E)	1.00	720.00	448,574.40
BLUE CARTRIDGES	(E)	2.00	200.00	124,604.00

BCV RATE: 623.02 Bs **TOTAL AMOUNT:** 7,274.44 \$ **4,532,121.61 BS**

NOTE: During the validity period of this estimate, the cost of materials and medications is subject to change. **PREPARED BY:** REBECA AGUILAR
 29/06/2026 01:46 PM

Some personal identification details have been covered to protect privacy while preserving the procedure and total cost.